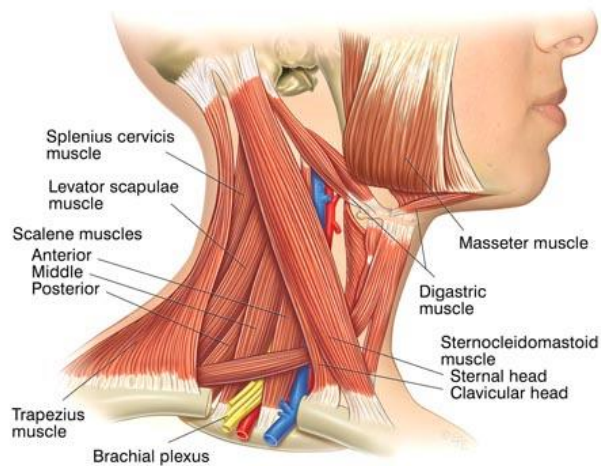
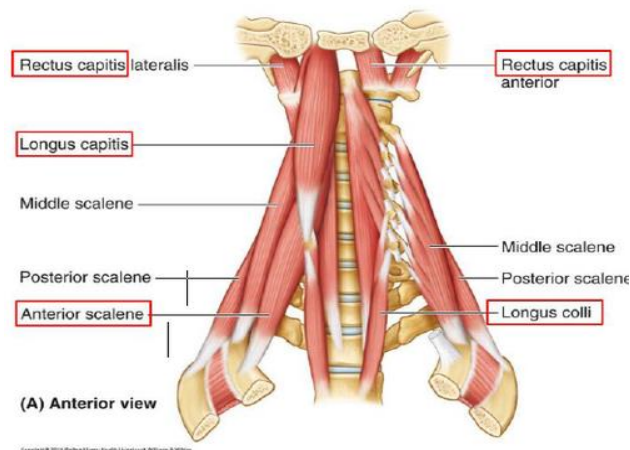
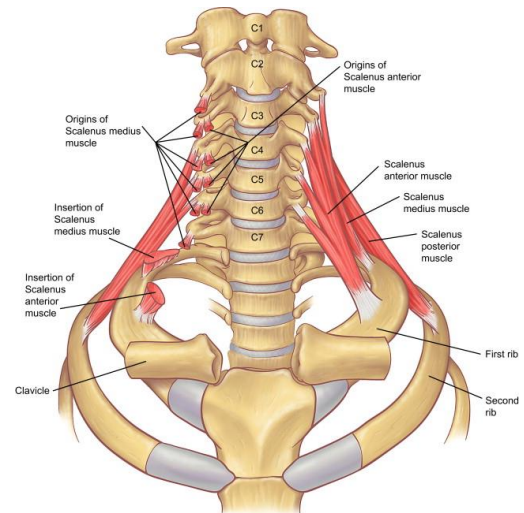
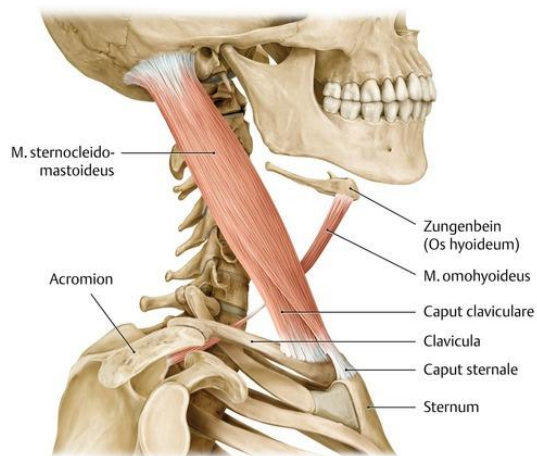
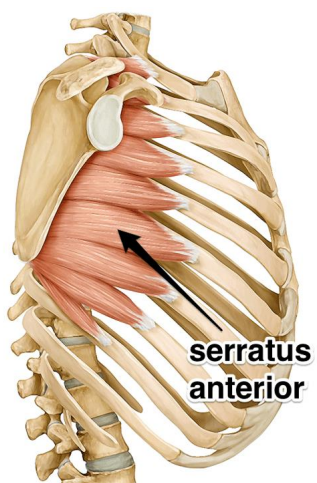
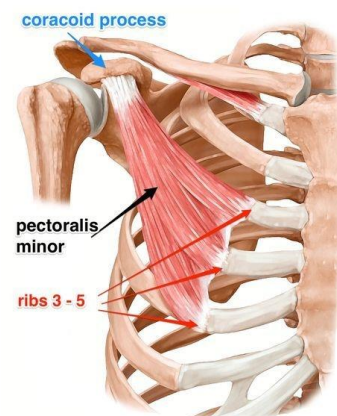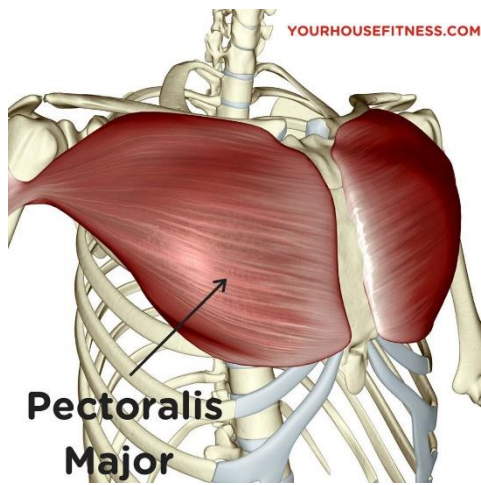


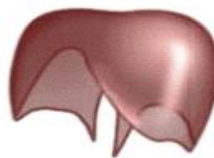## Svaly krku



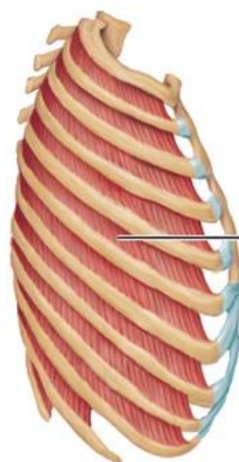
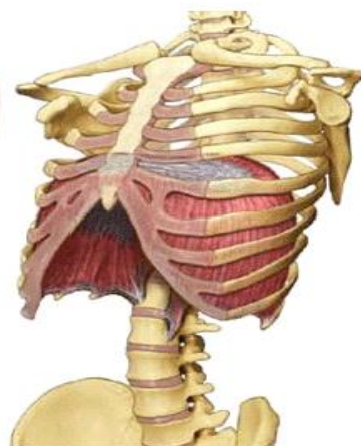
## Svaly hrudníku



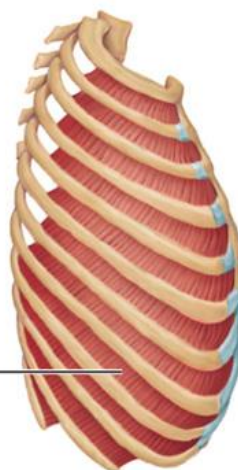
### Diafragma



El diafragma  
tiene forma  
de paracaídas

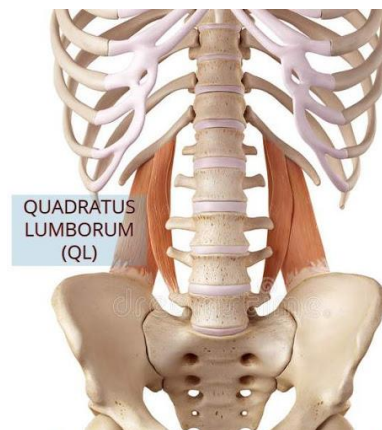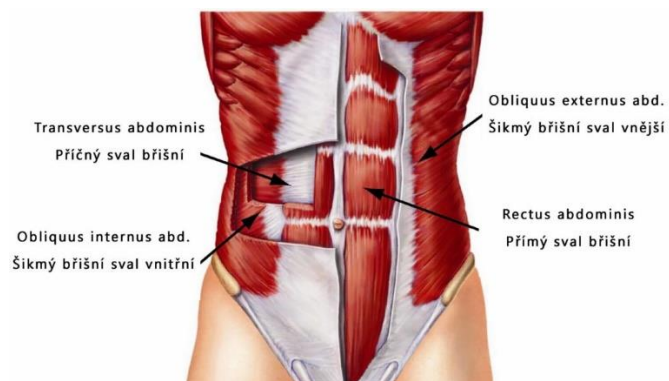
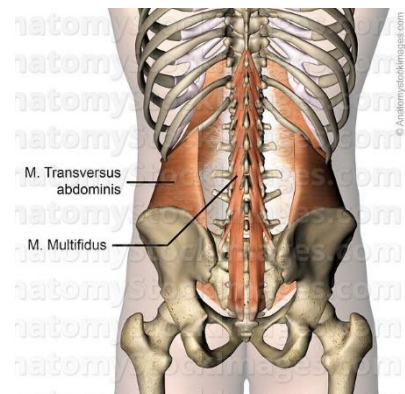
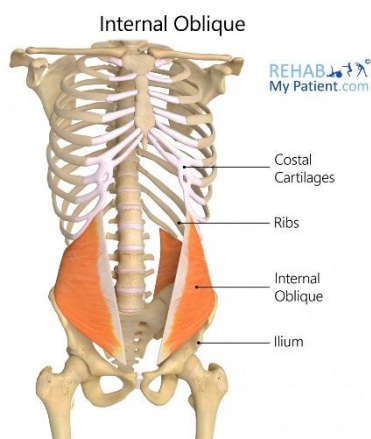
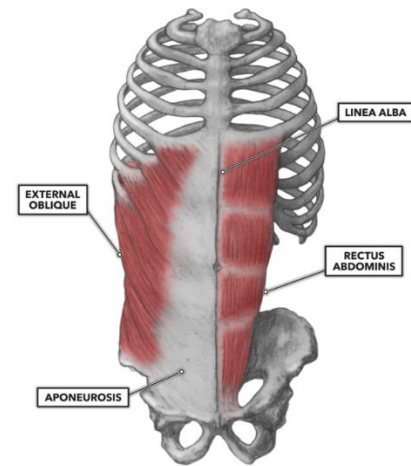
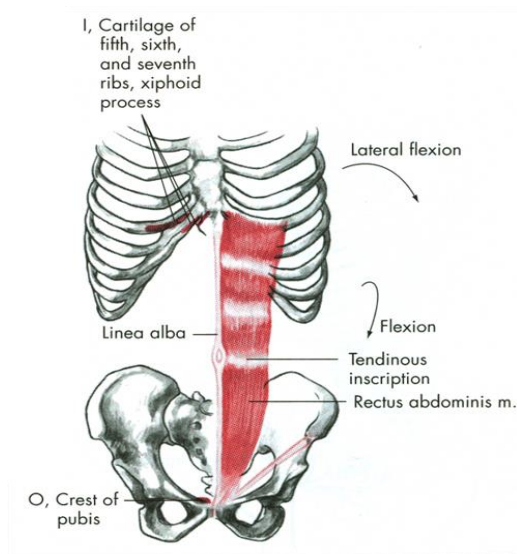


External  
intercostal

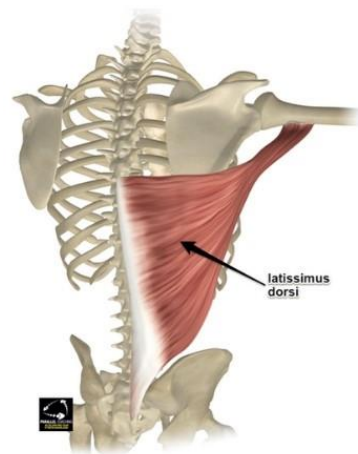
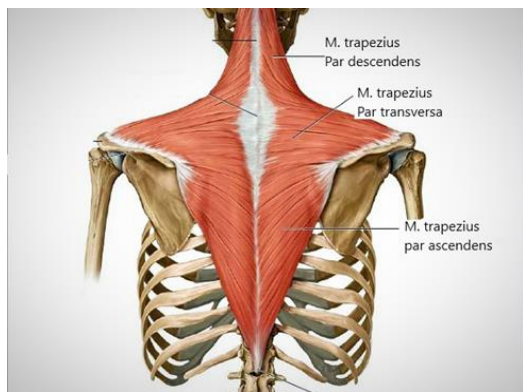


Internal  
intercostal

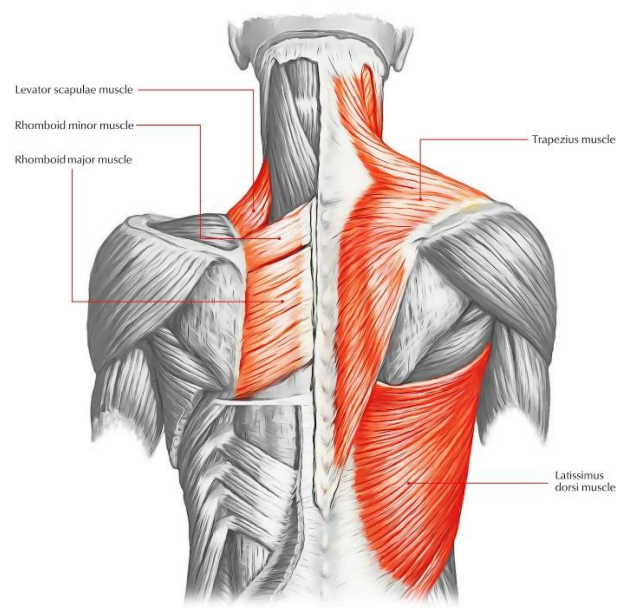
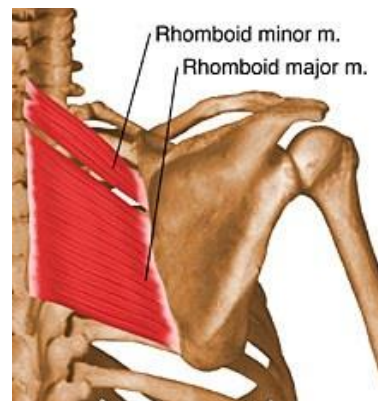
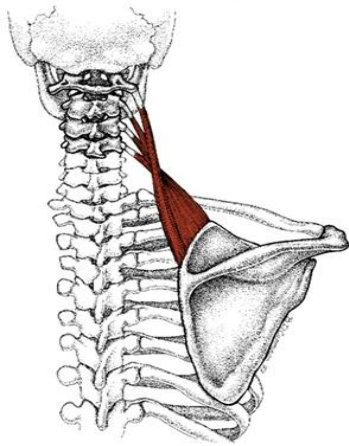
## Svaly břicha



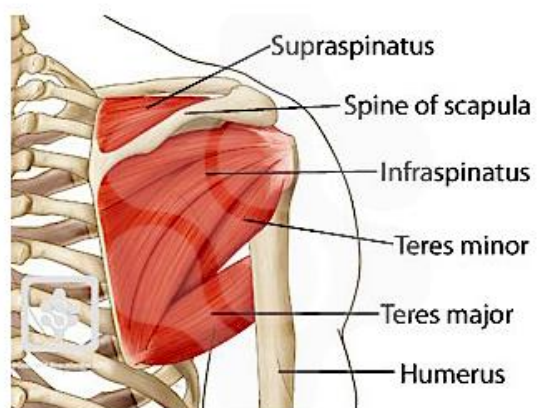
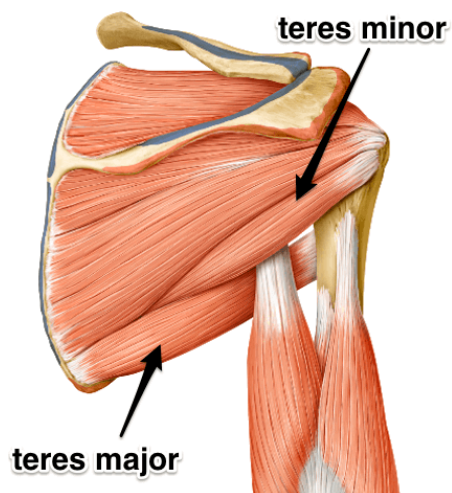
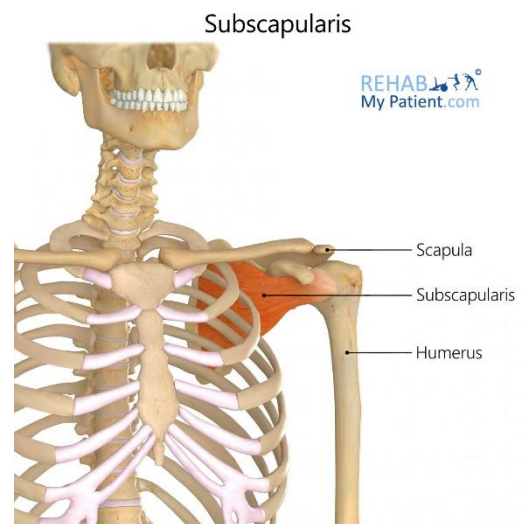
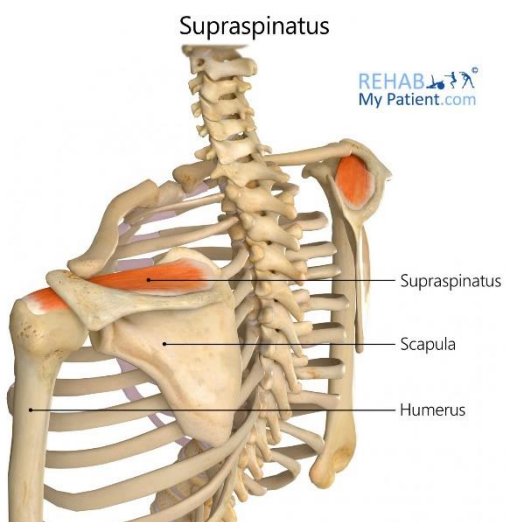
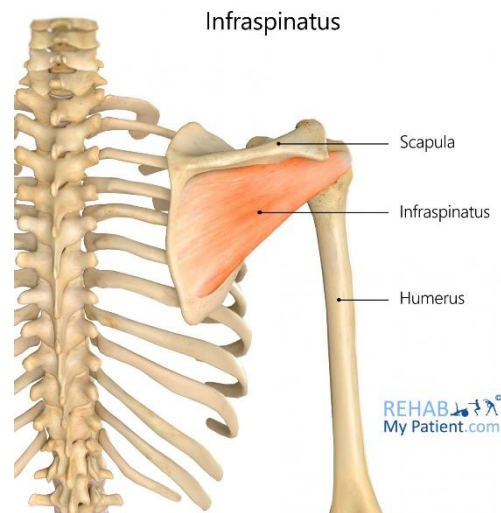
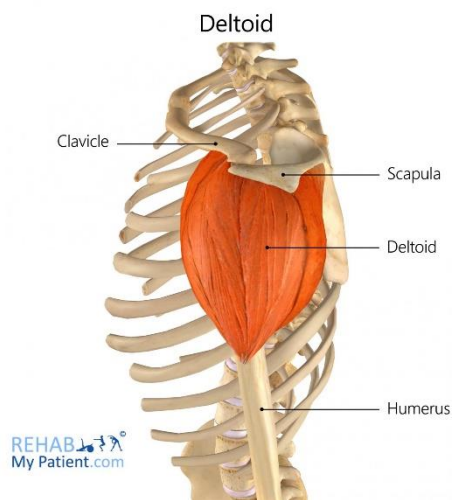
## Svaly zad

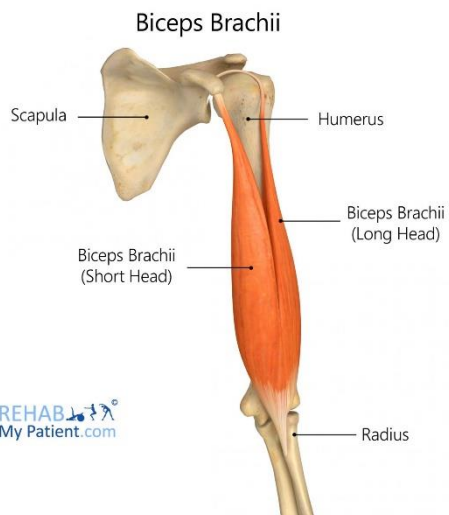


## Levator Scapulae



## Svaly HK

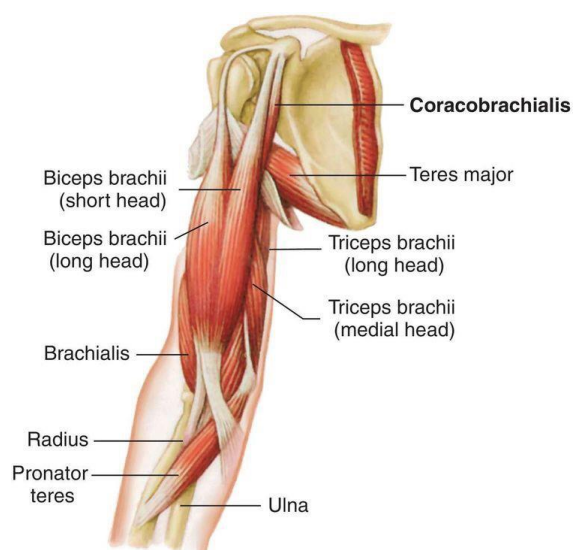
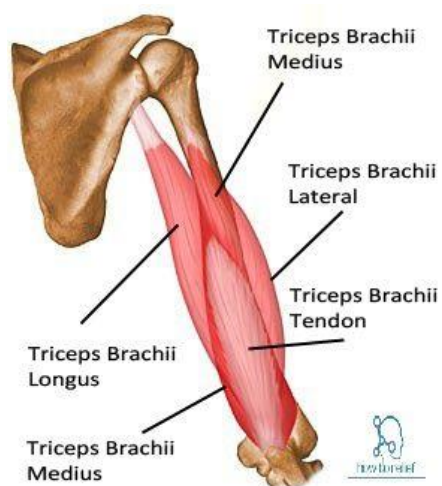
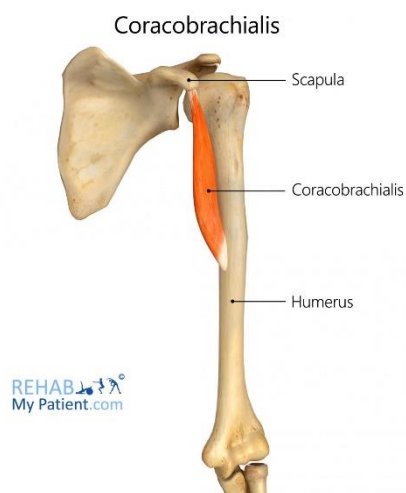
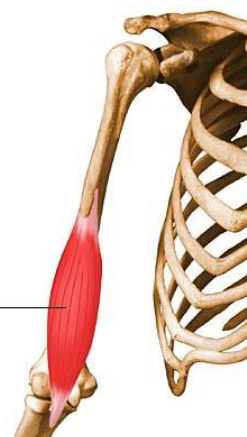

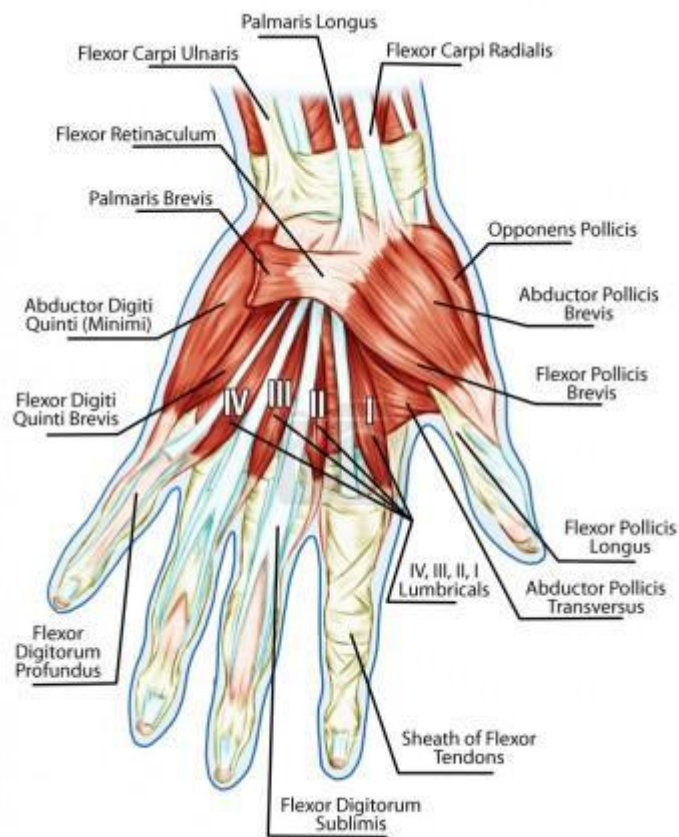
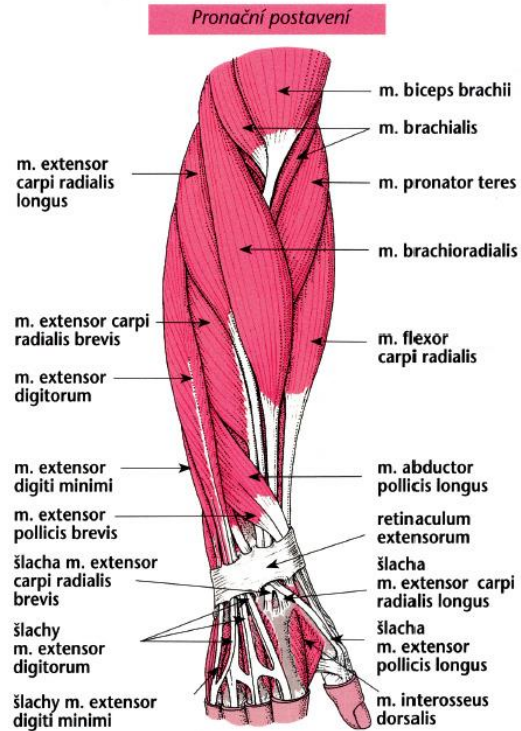
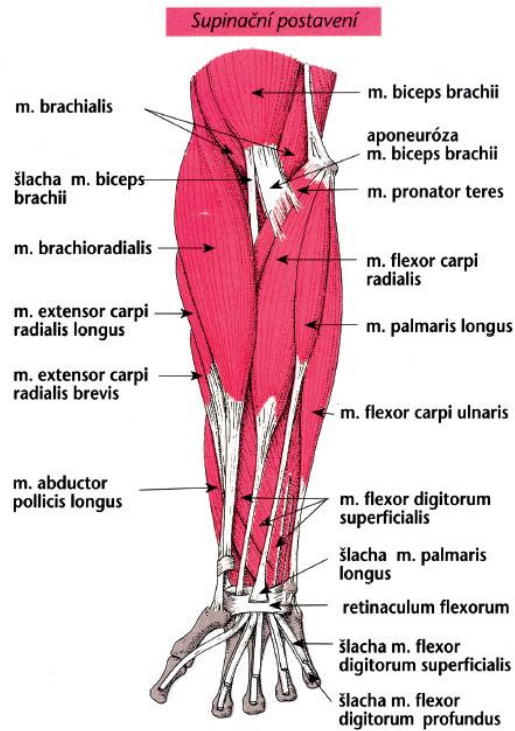


Svaly paže

m.brachialis  
hluboký sval pažni

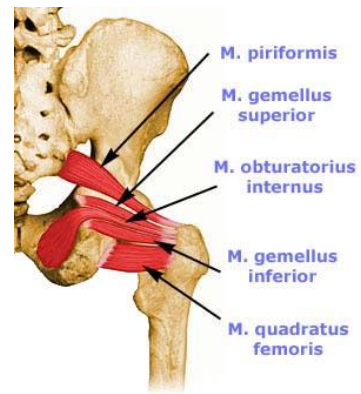
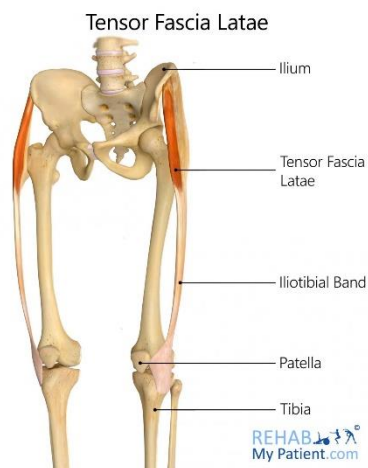
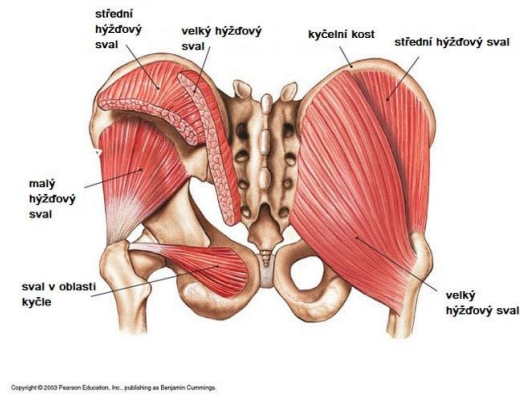
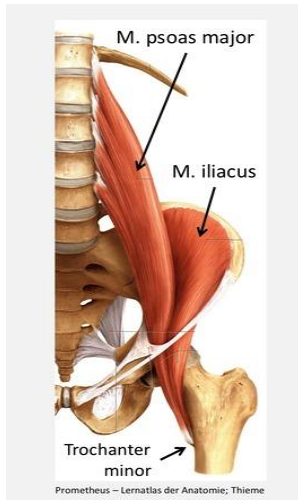
www.ronnie.cz



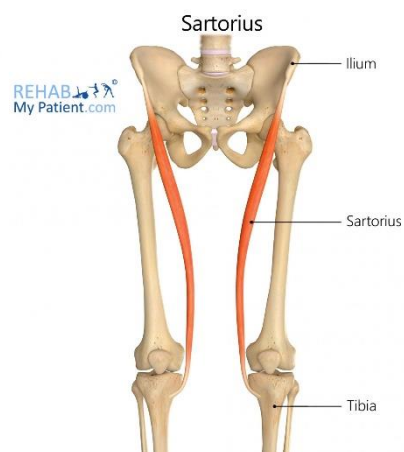
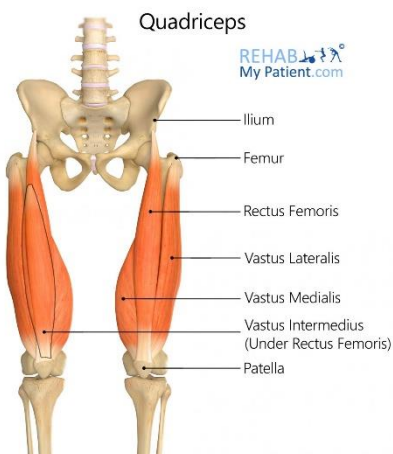


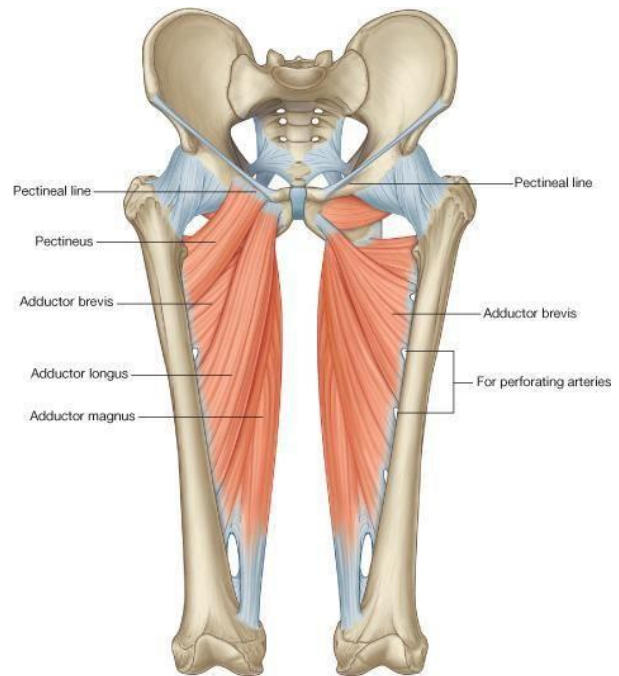
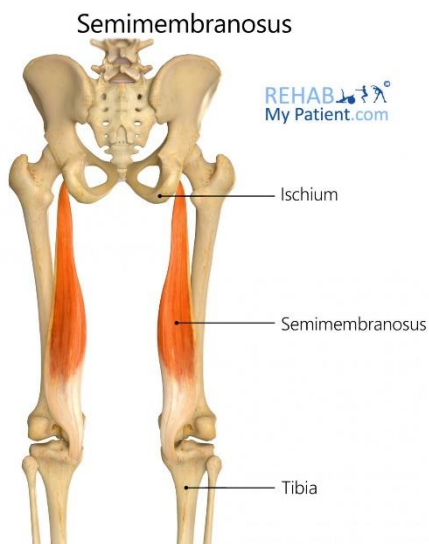
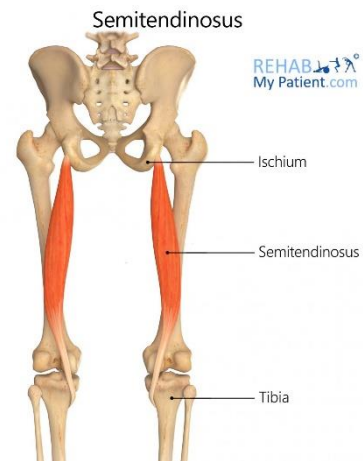
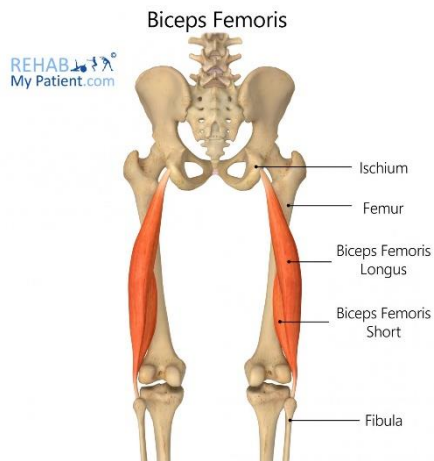


## Svaly DK

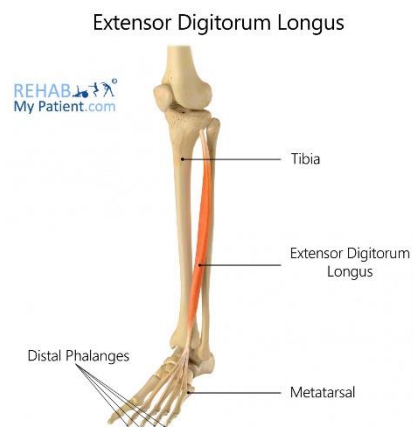
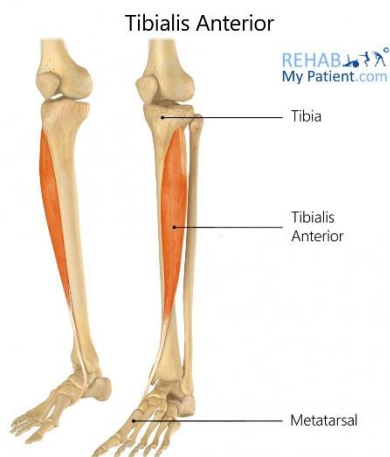

úprava: www.ronnie.cz

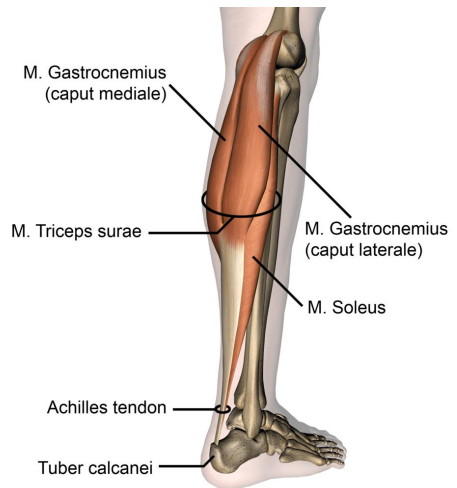
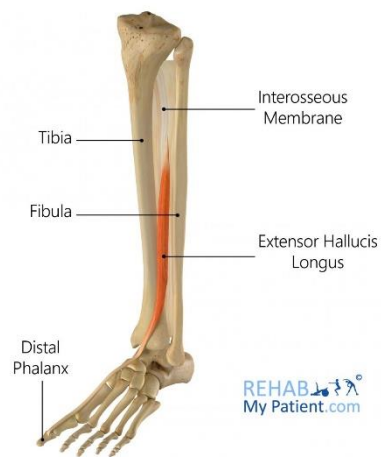



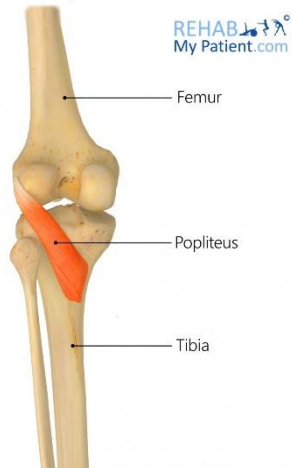
© Elsevier. Drake et al: Gray's Anatomy for Students - www.studentconsult.com



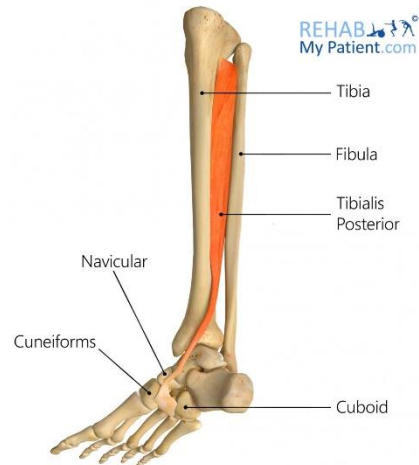
### Extensor Hallucis Longus



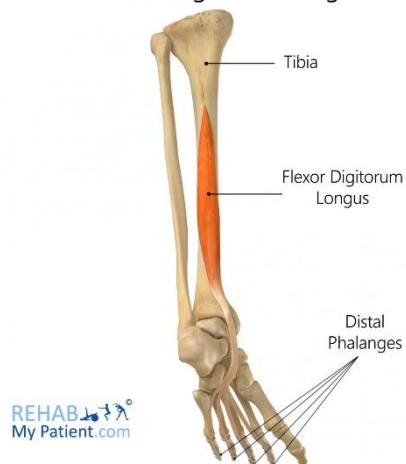
### Popliteus



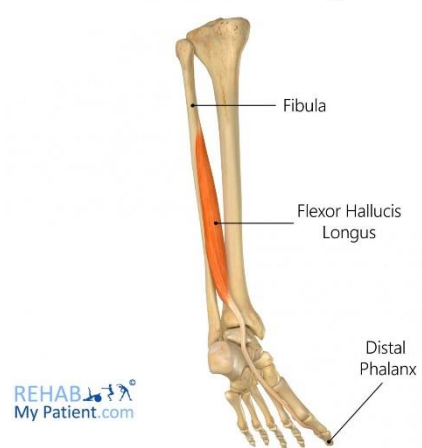
### Tibialis Posterior



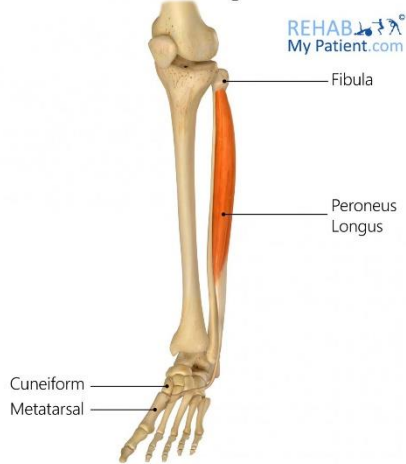
### Flexor Digitorum Longus



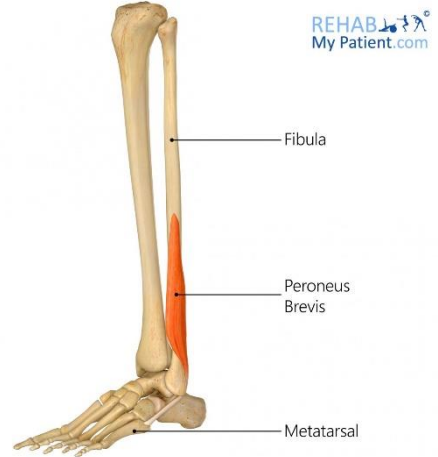
### Flexor Hallucis Longus



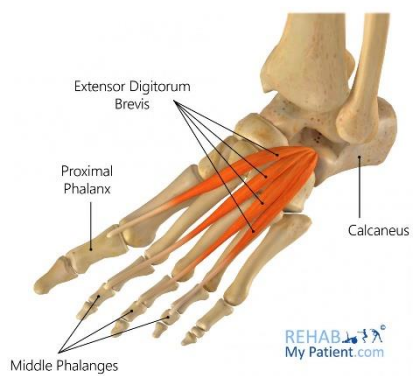
### Peroneus Longus



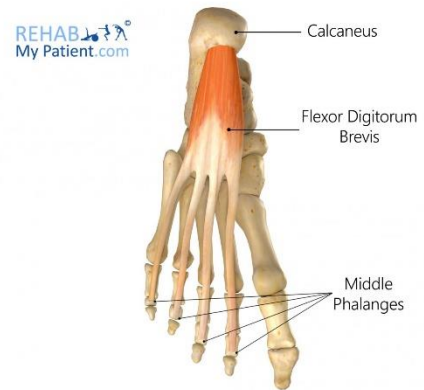
### Peroneus Brevis



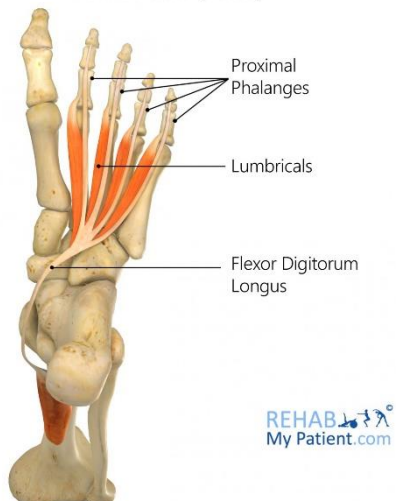
### Extensor Digitorum Brevis



### Flexor Digitorum Brevis



### Lumbricals (Foot)



### Dorsal Interossei (Foot)

